

*Original Article****Hydroxychloroquine Induced Retinopathy, a case series***Maryam Mobini¹ Ahmadzadeh-Amiri Ahmad² ***Khani Soghra**³

1- Associate professor, Rheumatologist, Research Center of Diabetes, Mazandran University of Medical Sciences, Sari, Iran.

2- Assistant Professor, Ophthalmologist, Research Center of Diabetes, Mazandran University of Medical Sciences, Sari, Iran.

3- Assistant Professor, Reproductive Health, Research Center of Diabetes, Department of Midwifery and Reproductive Health, Mazandran University of Medical Sciences, Sari, Iran.

khanisog343@gmail.com

(Received: 1 April 2016; Revised: 17 June 2016; Accepted: 10 September 2016)

Abstract

Background and Purpose: Ocular toxicity is one of the most important complications of Hydroxychloroquine. Not any type of treatment has so far been found and recommended for this disorder. The purpose of this study was to report some characteristics of patients with Hydroxychloroquine Induced Retinopathy.

Materials and Methods: From 107 patients with rheumatoid arthritis (RA) and/or systemic lupus erythematosus (SLE) during 2013-14 in Sari, Iran, who were selected by a simple sampling method and were referred to hospitals for ophthalmologic examinations, 21 patients were found with HCQ induced retinopathy. The Examination for HCQ-induced maculopathy was performed through fundoscopy, perimetry or optical coherence tomography (OCT), and the physicians had their own discretion based on the examination. Although the patients were examined by different ophthalmologists, all of them were evaluated by the same device (Zeiss cirrus HD OCT4000.USA for OCT, Zeiss Humphrey Field analyzer 2i. USA for visual field, and Topcon. TRC.50Dx. Japan for angiography). Based on the collected data, the characteristics of clinical and ophthalmologic changes were reported, and the data were analyzed through Independent Sample t Test and χ^2 .

Results: 21 patients (19 females) with a mean age of 49.86 (± 15.6) were evaluated during 4.95 (± 4.7) years of therapy. The mean of cumulative dose was calculated to be 313.18 \pm 269.8 grams. Based on the findings, hypertension was detected in 5 (23.8%) of the patients.

Conclusion: In the present study, it was found that HCQ induced retinal toxicity may occur even in recommended doses or for less than 5 years. Other risk factors such as hypertension in addition to the dose or duration of toxicity could also accelerate retinal toxicity.

Key words: Hydroxychloroquine; Antimalarial Agents; Retinal Toxicity

1. Introduction

Hydroxychloroquine ocular toxicity includes keratopathy, ciliary body involvement, lens opacities and retinopathy. The patients may be asymptomatic or complain about the difficulty in reading, decreased vision, missing central vision, glare, blurred vision, light flashes, and metamorphosis. Some patients with advanced retinopathy may experience deteriorated visual acuity even after HCQ discontinuation (1). There is no consensus on the definition of retinopathy, and it is whether called as the best

ophthalmological assessment, or the frequency of screening. No treatment exists yet for this disorder, and drug cessation is the only effective way to manage the toxicity (1, 2), so regular screening is necessary to detect reversible pre-maculopathy. The severity of toxic effects are categorized as early (patchy parafoveal damage shown on field or objective testing), moderate (50%-100% parafoveal ring of OCT thinning but intact retinal pigment epithelium) (Fig. 1) and severe (visible bull's-eye damage) (Fig. 2).

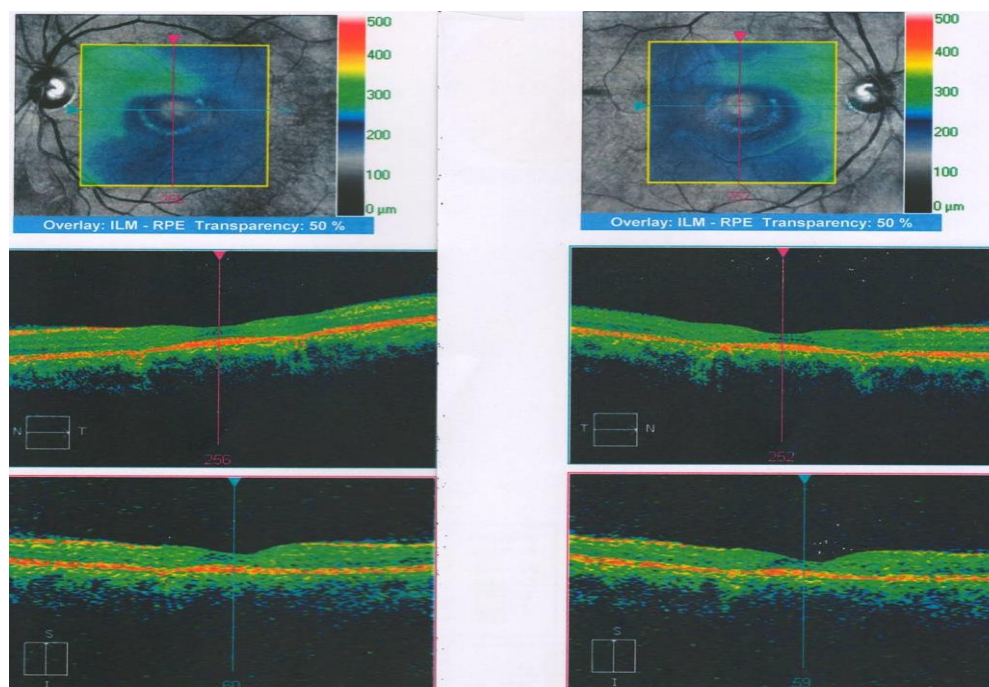


Fig 1. Patchy parafoveal damage shown on field or objective testing

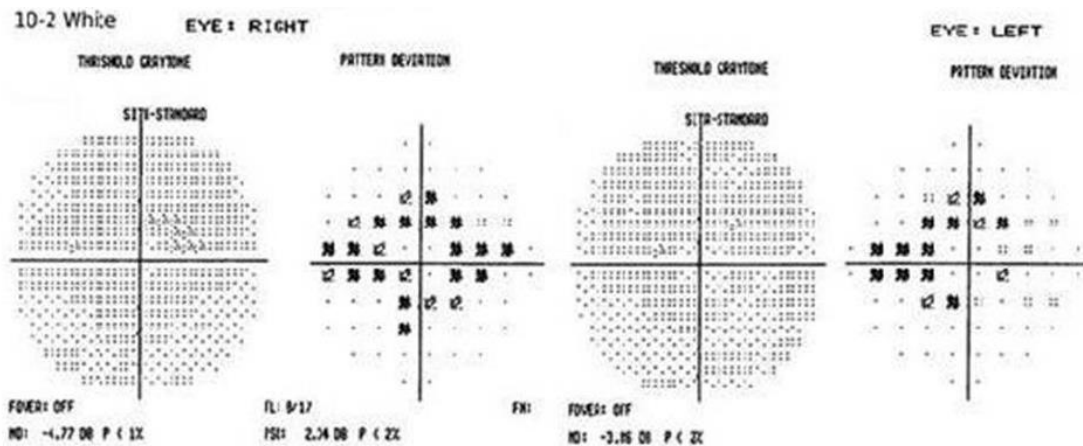


Fig 2. Visible bull's-eye damage

Early recognition of HCQ toxic effects before any fundus changes are visible, using automated 10-degree visual field test (Fig 3) and OCT will greatly minimize late progression and the risk of visual loss (3).

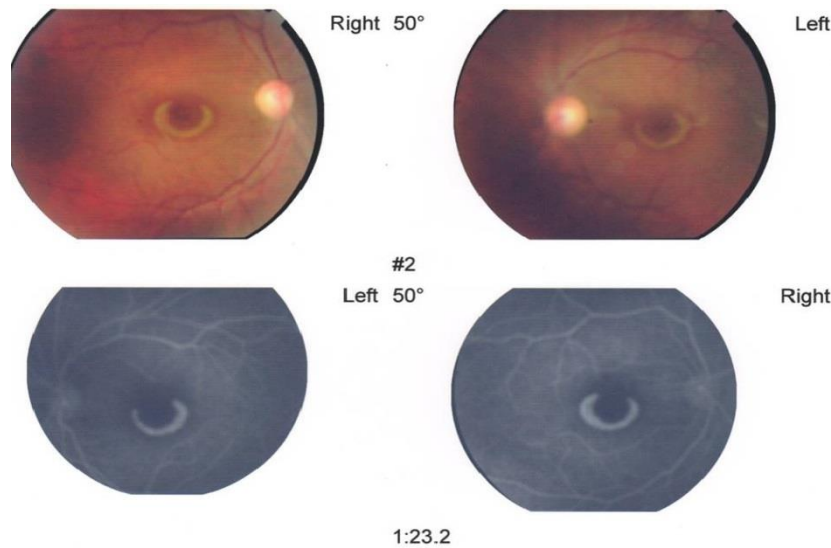


Fig 3. Automated 10-degree visual field test

For many years, it was believed that the incidence of true HCQ retinopathy is very low and less than 50 cases have been reported, but one of the most important causes of drug discontinuation is ophthalmologic adverse events (1, 4). HCQ-related maculopathy was formerly reported as 1.7% to 3.4% in long-term usage (5, 6), while the recent studies showed

that it may be more prevalent (7). Females (4), older age (>60) (4, 8), the prolonged use of the drug (>5 years) (2, 6, 8, 9), as well as dosage >6.5 mg/kg/day, liver/kidney disease, retinal disease, lack of eye examination are considered as risk factors for HCQ retinopathy (10). But in other studies, toxicity was not associated with age, daily dosage, weight, disease duration,

hypertension, and diabetes mellitus presence (9, 11). It is difficult to determine the most effective method for ocular examinations. These methods include visual field evaluation, color vision testing, fluorescence angiography, and electrophysiological tests. Because of the controversy about the selection of the best screening method for HCQ and chloroquine (CQ) retinopathy, the accurate prevalence of this disorder has not yet been made clear (1, 12). The American Academy of Ophthalmology recommendations for screening of HCQ maculopathy has introduced a baseline examination for patients starting the drug as a reference point, in order to rule out maculopathy, and annual screening after 5 years (or sooner if there are unusual risk factors). Objective tests, such as multifocal electro-retinogram (mfERG), spectral domain optical coherence tomography (SD-OCT), and fundus auto-fluorescence (FAF) can be more sensitive than visual fields. Fundus examinations are also recommended for documentation, but visible bull's-eye maculopathy is later changed, and the goal behind screening is to detect toxicity at an earlier stage (2). On the other hand, there are some reports on bulls-eye and other maculopathy presentation in HCQ treated patients occurring in less than 5 years or even few months or daily with a total dose of less than the later recommended dose (1, 12). So, it is necessary to discover other factors that may facilitate or contribute to retinal toxicity. The purpose of current study was then to report some characteristics of patients with Hydroxychloroquine Induced Retinopathy.

2. Materials and Methods

The study participants were a series of RA or SLE patients on HCQ who were complicated with retinopathy. 170 patients with RA and SLE who have used HCQ for at least one year were evaluated for retinopathy in Sari, north of Iran in the time period of 2013 to 2014. The patients have been referred to ophthalmologists because of annual examination.

The examination for HCQ-induced maculopathy has been done by fundoscopy, perimetry or optical coherence tomography (OCT) ophthalmoscope. Hence, the clinical and ophthalmologic characteristics of patients with HCQ-induced retinopathy were all described. Retinal changes due to diabetes or age-related maculopathy were also recognized according to ophthalmologic examination.

The cases for conducting the current study were defined as HCQ treatment discontinuation due to retinal toxicity according to the recommendation of ophthalmologist. Patients with hepatic or renal failure or other ophthalmologic problems such as uveitis were excluded. The reports with equivocal or doubtful results were not also included in the study.

The data collected from the patients included age, sex, height, body weight, daily and cumulative doses, treatment duration, rheumatic disorder, liver enzymes and serum creatinine, serology for rheumatoid factor (RF) or anti-nuclear antibody (ANA), corticosteroid use.

The data related to diseases in addition to ophthalmologic examination results were all then recorded. Therefore, the principles outlined in the Declaration of Helsinki of the World Medical Association were all followed in the current study.

The collected data was then analyzed through descriptive statistics for mean and Standard Deviation in quantitative variables by SPSS 17.

3. Results

From 170 patients with RA (142 patients, 83.5%) and SLE (28 patients, 16.5%), 21 patients were found with HCQ induced retinopathy. The mean age of the participants was 49.86 (± 15.6), and the duration of therapy was 4.95(± 4.7) years. The mean of daily dose and cumulative dose were calculated to be 2.83 ± 0.8 mg/ Kg and 313.18 ± 269.8 grams, respectively. Hypertension was also detected in five of the study participants.

The patients concomitantly consumed prednisolone (95%), methotrexate (66.6%), and azathioprine (14.28%). The clinical and ophthalmic analyses of the research were all recorded in table 1.

Table 1. Characteristics of patients with HCQ induced retinopathy.

Patient number	Age	Sex	Disease	Antibody serology	BMI	Other disease	Duration of HCQ treatment (years)	Daily dose (mg)	Ophthalmologic examination	Damage
1	54	F	RA	RF+, Anti CCP+	34.5	Hypertension	16	200	Fundoscopy	Maculopathy
2	59	F	RA	RF+, Anti CCP+	35.4	Hypertension	1	200	Fundoscopy, SD-OCT and perimetry	Central vision disorder and maculopathy
3	52	F	RA	RF+, Anti CCP+	35.4	-	4	200	Fundoscopy	Maculopathy
4	72	F	RA	RF+	43.6	Hypertension	3	200	Fundoscopy and perimetry	Central vision disorder and maculopathy
5	55	M	RA	RF+	25.7	Hypertension-Hypothyroidism	10	200	Fundoscopy, SD-OCT and Angiography	Bull's eye maculopathy
6	20	F	RA	RF+, Anti CCP+	30	-	3	200	Fundoscopy	Maculopathy
7	44	F	RA	RF+, Anti CCP+	28	-	2	200	Fundoscopy	Maculopathy
8	44	F	SLE	ANA+	22.2	-	2	200	Fundoscopy and perimetry	Maculopathy and defects of visual field
9	48	F	RA	Negative	29.2	-	4	200-400	Fundoscopy and perimetry	Maculopathy and defects of central visual field
10	55	F	RA	RF+	25.3	-	10	200	Fundoscopy and perimetry	Several defects in visual field
11	71	F	RA	RF+	29.3	-	18	200	Fundoscopy	Maculopathy
12	47	F	SLE	ANA+	29.3	-	4	400	Fundoscopy, SD-OCT	Severe maculopathy
13	21	F	SLE	ANA-, DsDNA+	28.7	-	2	200	Fundoscopy and perimetry	Maculopathy and defects of visual field
14	53	F	RA	RF+	24.4	-	4	200	Fundoscopy	Maculopathy
15	61	F	RA	RF+, Anti CCP+	34.8	-	4	100	Fundoscopy and perimetry	Maculopathy and defects of visual field
16	23	F	SLE	ANA+, DsDNA+	29.4	-	2	400	Fundoscopy and perimetry	Maculopathy and defects of visual field
17	50	M	RA	RF+, Anti CCP+	25.8	-	2	200	Fundoscopy and perimetry	Maculopathy and defects of visual field
18	66	F	RA	RF+	30.7	-	7	200	Fundoscopy	Maculopathy
19	40	F	RA	RF+, Anti CCP+	35.1	-	2	200	Fundoscopy and perimetry	Maculopathy and defects of visual field
20	36	F	RA	RF+, Anti CCP+	29.5	-	2	200	Fundoscopy and perimetry	Maculopathy and defects of visual field
21	77	F	RA	RF+	33.3	Diabetes mellitus, hypertension	9	200	Fundoscopy and perimetry	Maculopathy and defects of visual field

Then the patients with retinal toxicity were compared with other patients. They were found to be similar in sex, age, body mass index (BMI), blood chemistries, rheumatologic disorder, underlying disease such as diabetes or hypothyroidism, seropositivity for RF or ANA,

HCQ dose (total and mg/kg), and duration or cumulative dose and DMARDs, except for azathioprine consumption which was more prevalent in patients with retinal damage ($P=0.049$), Table 2.

Table 2. Demographic and basic characteristics of the patients with / without hydroxychloroquine maculopathy

Variable	Patients with HCQ maculopathy (n=21)	Patients without HCQ maculopathy (n=149)	P. value
Age (years)	49.86±15.86	50.27±13.76	0.9
Sex (female): N (%)	19 (90.5)	137 (91.9)	0.8
BMI (kg/m ²)	31.49 ±5.2	29.27±6.1	0.8
Duration of HCQ usage (years)	4.95±4.7	3.8±2.9	0.3
cumulative dose (grams)	313.18±269.8	270±226	0.8
Hx of DM: N (%)	1 (4.8)	16 (10.7)	0.6
Hx of hypertension: N (%)	5(23.8)	24 (16.1)	0.1
Hx of hypothyroidism: N (%)	1 (4.8)	16 (10.7)	0.6

4. Discussion

This study showed retinal toxicity in 12.3% of the patients who were treated by HCQ. The mean of daily dose/weight was 2.83 ± 0.8 mg/kg, and HCQ cumulative dose was 313.18 ± 269.8 g with a duration of about 5 years. It means that HCQ consumption as 200 mg/day for less than 5 years may be adequate to predispose the patients to retinal toxicity. On the other hand, it was found that the duration of HCQ consumption for the eight patients with retinal toxicity was two years or fewer. So, some other unknown factors other than dose and duration of treatment may have influence on its toxicity.

The evaluation of prevalence of anti-malarias-induced retinopathy is difficult, because the selection of patients or methods of ophthalmologic examination are different. The different methods used for this purpose include: 10-2 automated fields, multifocal electroretinography, spectral domain optical coherence tomography (SD-OCT), and fundus

autofluorescence (13). 13.1% to 24.7% of the patients were reported to be on HCQ or CQ treatment, and a trend for a higher risk was observed in the case of chloroquine (CQ) treatment (7,11,14). In the patients who were treated by HCQ, bull's eye maculopathy, visual field loss, or other irreversible retinal toxicity were considered as definite or probable toxicity, which was only in 0.5-0.65% of the cases (5, 9). In a retrospective review of the results of ophthalmologic examination, electroretinogram, electro-oculogram, colour vision test, and central visual field in two centers were used to assess anti-malarias retinal intoxication, the results of which included 5.4% and 4% of the patients with preclinical intoxication, and 1.4% and 0.4% with clinical intoxication, respectively (15).

The history of concomitant HTN was found in 5 (23.8%) and 24 (16.1%) of the patients with and without retinopathy ($p=0.1$). In the study of Kobak et al. study, HTN and DM presence had no statistically significant effect on

retinopathy development (11), but in another study, arterial hypertension had a statistically significant effect on anti-malaria retinopathy development (7).

There is no consensus on the effect of the basic characteristics of patients, such as age, daily dose and BMI of the disease (4,8,9). The mean of daily dose was 204.76 (\pm 49.8) mg and cumulative dose was 313.18 \pm 269.8 g. The duration of HCQ consumption was also 4.95 (\pm 4.7) years. In the study of Palma Sanchez et al., the mean daily was 333 mg and the mean cumulative dose was 111 g (7). At the same time, the mean duration of hydroxychloroquine therapy was 13 years (range, 2-20) in another study (16), while the mean of daily dose/weight was 2.83 \pm 0.8 mg/kg, which could be compatible with the results of previous case series (17). It means that these known risk factors may not be good predictors for HCQ maculopathy.

The results of the study indicated that both race and genetics may influence retinal toxicity and its pattern especially among Asian patients (18). Hence, the observed genetic susceptibility in the participant patients of the present study may be the subject of future studies. On the other hand, different methods of ophthalmologic examination might influence retinopathy detection. So, some extensive but regional studies with similar methodologies for ophthalmologic examination should be conducted in order to evaluate the other risk factors such as HTN, drug interactions, and genetics.

One main limitation of the current study was the examination of patients by different ophthalmologists through different methods.

5. Conclusion

Macular changes, which are considered as late manifestations, were reported in 12.3% of the patients who were treated by HCQ. However, some other patients with milder changes were not reported. It should finally be noted that HCQ therapy still requires intensive monitoring to avoid severe retinal damage that can lead to blindness.

Acknowledgement

We appreciate all those patients who participated in the study.

Conflict of interest: The authors declare no conflict of interest.

References

1. Yam J, Kwok A. Ocular toxicity of hydroxychloroquine.. Hong Kong Med J. 2006; 12(4):294-304.
2. Marmor MF, Kellner U, Lai TY, Lyons JS, Mieler WF. Revised recommendations on screening for chloroquine and hydroxychloroquine retinopathy. Ophthalmology. 2011;118(2):415-22. Epub 2011/02/05.
3. Marmor MF, Hu J. Effect of Disease Stage on Progression of Hydroxychloroquine Retinopathy. JAMA ophthalmology. 2014. Epub 2014/06/13.
4. Jover JA, Leon L, Pato E, Loza E, Rosales Z, Matias MA, et al. Long-term use of antimalarial drugs in rheumatic diseases. Clinical and experimental rheumatology. 2012;30(3):380-7. Epub 2012/02/22.
5. Mavrikakis I, Sfikakis P, Mavrikakis E, Rougas K, Nikolaou A, et al. The incidence of irreversible retinal toxicity in patients treated with hydroxychloroquine: a reappraisal. Ophthalmology. 2003; 110(7): 1321-6.

6. Levy G, Munz S, Paschal J, Cohen H, Pince K, Peterson T. Incidence of hydroxychloroquine retinopathy in 1,207 patients in a large multicenter outpatient practice. *Arthritis Rheum.* 1997; 40(8): 1482-6.
7. Palma Sanchez D, Rubio Velazquez E, Soro Marin S, Reyes Garcia R. Retinal toxicity due to antimalarials: frequency and risk factors. *Reumatologia clinica.* 2013;9(5):259-62. Epub 2013/05/28.
8. Bergholz R, Schroeter J, Ruther K. Evaluation of risk factors for retinal damage due to chloroquine and hydroxychloroquine. *The British journal of ophthalmology.* 2010; 94(12): 1637-42. Epub 2010/10/14.
9. Wolfe F, Marmor M. Rates and predictors of hydroxychloroquine retinal toxicity in patients with rheumatoid arthritis and systemic lupus erythematosus. *Arthritis Care Res (Hoboken)* 2010;62(6):775-84.
10. Flach AJ. Improving the risk-benefit relationship and informed consent for patients treated with hydroxychloroquine. *Transactions of the American Ophthalmological Society.* 2007;105:191-4; discussion 5-7. Epub 2008/04/23.
11. Kobak S, Deveci H. Retinopathy due to antimalarial drugs in patients with connective tissue diseases: are they so innocent? A single center retrospective study. *Int J Rheum Dis.* 2010;13(3:e):11-5.
12. BROWNING D. Hydroxychloroquine and chloroquine retinopathy: screening for drug toxicity. *American journal of ophthalmology.* 2002;649-56.
13. Marmor MF. Comparison of screening procedures in hydroxychloroquine toxicity. *Archives of ophthalmology.* 2012; 130(4): 461-9. Epub 2011/12/14.
14. Yaylali SA, Sadigov F, Erbil H, Ekinci A, Akcakaya AA. Chloroquine and hydroxychloroquine retinopathy-related risk factors in a Turkish cohort. *International ophthalmology.* 2013;33(6):627-34. Epub 2013/03/05.
15. Bui Quoc E, Ingster-Moati I, Rigolet M, Chosidow O, Bodaghi B. Ophthalmologic prevention of chloroquine and hydroxychloroquine induced retinopathy. *Ann Dermatol Venereol.* 2005;132(4):329-37.
16. Michaelides M, Stover NB, Francis PJ, Weleber RG. Retinal toxicity associated with hydroxychloroquine and chloroquine: risk factors, screening, and progression despite cessation of therapy. *Archives of ophthalmology.* 2011;129(1):30-9. Epub 2011/01/12.
17. Ingster-Moati I, Bui Quoc E, Crochet M, Orssaud C, Dufier JL, Roche O. [Severe chloroquine- and hydroxychloroquine-induced retinopathy]. *Journal francais d'ophtalmologie.* 2006;29(6):642-50.
18. Melles RB, Marmor MF. Pericentral retinopathy and racial differences in hydroxychloroquine toxicity. *Ophthalmology.* 2015;122(1):110-6.